



## Rare case of dural arteriovenous fistula presenting by spontaneous acute subdural hematoma – A case report and review of literature

Redak slučaj prezentacije duralne arteriovenske fistule putem spontanog akutnog subduralnog hematoma

Jagoš Golubović, Djula Djilvesi, Tomislav Cigić, Vladimir Papić,  
Bojan Jelača, Petar Vuleković

Clinical Centre of Vojvodina, Clinic of Neurosurgery, Novi Sad, Serbia; University of  
Novi Sad, Faculty of Medicine, Novi Sad, Serbia

### Abstract

**Introduction.** Dural arteriovenous fistulas represent pathological acquired bonds between the meningeal blood vessels (arteries) and drainage veins associated to them. These fistulas can vary in clinical presentations, from being asymptomatic to causing serious neurological deficits, depending mostly on the localization and size. Only one fourth of dural fistulas present themselves with intracranial bleeding. This hemorrhage is most frequently localized in subarachnoid space, occasionally intracerebrally, and seldom beneath the dura mater, *ie* subdurally. **Case report.** We presented a rare case of a patient with spontaneous acute subdural hematoma. After the initial treatment and consequent imaging methods, a diagnosis of a dural arteriovenous fistula was established. After the craniotomy for hematoma evacuation, the patient underwent an uneventful endovascular treatment. Despite the rarity of non-traumatic acute subdural hematoma caused by dural arteriovenous fistula, one should not overlook the possible pathogenesis and etiology in patients with spontaneous acute subdural hematoma. Even with the absence of the symptoms and signs of subdural bleeding, dural arteriovenous fistula, as a cause of it, should not be immediately ruled out. **Conclusion.** Despite the rarity of non-traumatic acute subdural hematoma being caused by dural arteriovenous fistulas, one should not immediately overlook the possible pathogenesis and etiology. Cautious approach is needed when treating such diseases even in the absence of typical symptoms.

### Key words:

central nervous system vascular malformation; hematoma, subdural; diagnosis; neurosurgical procedures; treatment outcome.

### Apstrakt

**Uvod.** Duralne arteriovenske fistule predstavljaju patologiju koju odlikuju veze između meningealnih krvnih sudova i njima pripadajućih drenažnih vena. Klinička prezentacija ovih fistula je različita i najviše zavisi od lokalizacije i veličine istih. Mogu biti asimptomatske, a mogu se ispoljavati kao ozbiljni neurološki deficit. Samo jedna četvrtina ovih malformacija se prezentuje kao intrakranijalno krvarenje, najčešće lokalizovano subarahnoidalno, potom intracerebralno, a retko ispod tvrde moždane opne, tj. subduralno. **Prikaz bolesnika.** U radu je prikazan bolesnik sa spontanim akutnim subduralnim hematomom. Nakon inicijalnog tretmana i posledičnih dijagnostičkih metoda, utvrđeno je postojanje duralne arteriovenske fistule. Nakon kraniotomije i evakuacije hematoma bolesnik je podvrgnut endovaskularnom tretmanu bez posledica. Uprkos retkoj pojavi netraumatskog akutnog subduralnog hematoma uzrokovanog duralnom arteriovenskom fistulom, ne bi trebalo prevideti moguću patogenezu i etiologiju ove bolesti. Čak i prilikom izostanka tipičnih simptoma subduralnog krvarenja, ne treba isključiti mogućnost nastanka istog zbog postojanja duralne arteriovenske fistule. **Zaključak.** Iako je pojava netraumatskog akutnog subduralnog hematoma uzrokovanog duralnom arteriovenskom fistulom retka, potencijalna patogenezna i etiologija se ne sme odmah isključiti. Oprezan pristup je nužan tokom lečenja ove vrste bolesti, čak i kod izostanka tipičnih simptoma.

### Ključne reči:

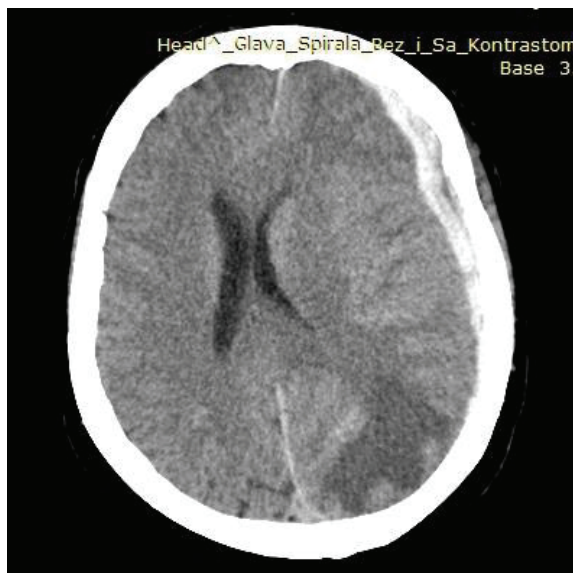centralni nervni sistem, vaskularne malformacije; hematoma, subduralni; dijagnoza; neurohirurške procedure; lečenje, ishod.

## Introduction

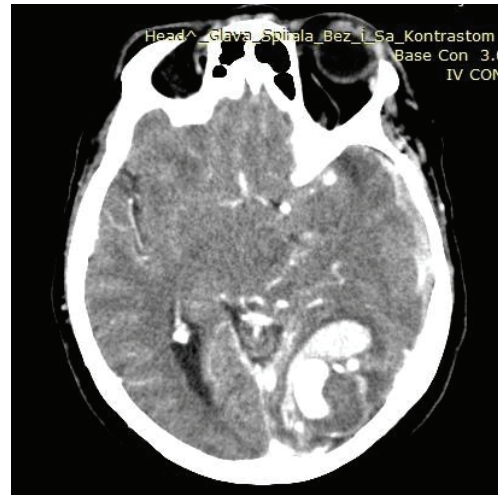
Dural arteriovenous fistulas (DAVF) are usually defined as pathologically acquired bonds between the meningeal blood vessels (arteries) and drainage veins associated to them<sup>1</sup>. Depending mostly on the localization and size, these fistulas can vary in clinical presentation, from being asymptomatic to causing serious neurological deficits<sup>2</sup>. In 24% of the cases they present themselves with intracranial hemorrhage, most often as subarachnoid or intracerebral hemorrhage<sup>1-3</sup>. An acute subdural hematoma (aSDH) caused by a DAVF occurs rarely<sup>1-3</sup>. There have been only a few reports of aSDH caused by DAVF in the literature<sup>2,4-7</sup>.

## Case report

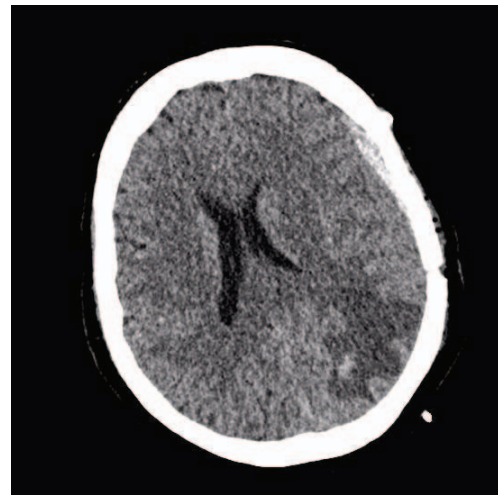
A 66-year-old previously healthy female presented with alteration of consciousness which followed the previous loss of it. Initially the patient was unconscious, and upon awakening displayed symptoms of confusion and drowsiness. She was brought to our emergency clinic for neurological care. On the admission, the patient was confused, opening eyes to voice, obeying commands, Glasgow Coma Score (GCS) was 13. She had no signs of motor or cranial nerve deficits, and her pupils were isochoric and photo-reactive, while the meningeal signs were absent. Initial computed tomography (CT) head scan showed an aSDH on the left convexity of cranium with mass effect (Figure 1). With no confirmed traumatic brain injury (TBI), CT angiography (CTA) was performed showing early opacification located parietooccipitally on the left side (Figure 2). Patient underwent trauma flap craniotomy, and the aSDH was evacuated. During the postoperative hospitalization patient's GCS score was 15 with no neurological deficits, while the postoperative CT scan showed adequate aSDH evacuation (Figure 3).



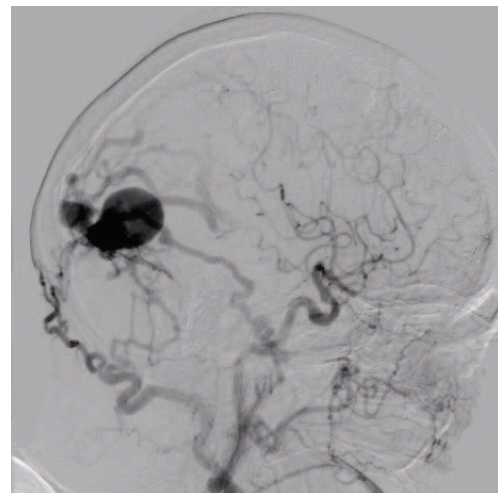
**Fig. 1 – Computed tomography (CT) axial head scan depicting a hyperdense lesion of acute subdural hematoma (aSDH) on the left convexity of cranium with mass effect.**



**Fig. 2 – Computed tomography angiography (CTA) presenting early opacification located parietooccipitally on the left side.**



**Fig. 3 – Post-operative computed tomography (CT) scan showing adequate hematoma evacuation.**



**Fig. 4 – Digital subtraction angiography (DSA) showing opacification of the left external carotid artery as well as of the right occipital artery draining via drainage veins into sagittal, transversal and straight sinus.**

Digital subtraction angiography (DSA) performed postoperatively (Figure 4) demonstrated opacification of the left external carotid artery as well as opacification of the right occipital artery draining, via bulging drainage veins into sagittal, transversal and straight sinus, thus confirming an intracranial DAVF (Figure 1). After the initial hematoma evacuation and postoperative follow-up, endovascular treatment, embolization of the DAVF with Onyx, was the method of choice for the patient. The patient was uneventful since the discharge period.

### Discussion

Dural arteriovenous fistulas make around 10–15% of all neurosurgical arteriovenous lesions<sup>1</sup>. Most often they are fed by external carotid artery or, less frequently, by the internal carotid and vertebral arteries (meningeal arteries), while being drained through dural or leptomeningeal veins<sup>1,2</sup>. The clinical course of DAVF varies. Depending mostly on the localization and size, presentation can range from being asymptomatic or mildly symptomatic (eg. headache, tinnitus) to causing serious progressive neurological deficits<sup>1,3</sup>.

Only 24% of dural fistulas present themselves with intracranial bleeding, and that hemorrhage is most commonly

localized in subarachnoid space, occasionally intracerebrally, and very rarely beneath the dura mater, *ie* subdurally<sup>1, 6</sup>. Therefore, a case of a non-traumatic acute SDH caused by a DAVF can be considered a very rare pathology<sup>1,2,4-7</sup>. Current literature explains the occurrence of aSDH by the rupture of the bulged draining vein which was being overflowed with blood from the feeding meningeal artery<sup>1,2,5</sup>. At the moment of writing this paper, endovascular treatment with Onyx is considered to be the first line of strategy whereas the operative treatment should be performed only if consecutive endovascular interventions fail<sup>1</sup>.

Leptomeningeal retrograde venous drainage present in CTA imaging increases the risk of intracranial bleeding from DAVF, and this is why the venous part of the fistulas are of greatest importance for the occurrence of hemorrhage<sup>1,2,6</sup>.

### Conclusion

Despite the rarity of non-traumatic aSDH caused by DAVF, one should not immediately overlook the possible pathogenesis and etiology in patients with spontaneous aSDH. Even with the absence of the symptoms and signs that subdural bleeding is caused by DAVF, it should not be immediately ruled out.

### R E F E R E N C E S

1. Rivera-Lara L, Gailloud P, Nyquist P. Diploic arteriovenous fistulas—classification and endovascular management. *Acta Neurochir (Wien)* 2015; 157(9): 1485–8.
2. De Aguiar GB, Veiga JCE, De Almeida Silva JM, Conti ML. Spontaneous acute subdural hematoma: A rare presentation of a dural intracranial fistula. *J Clin Neurosci* 2016; 25: 159–60.
3. Fischbein NJ, Wijman CA. Nontraumatic intracranial hemorrhage. *Neuroimaging Clin N Am* 2010; 20(4): 469–92.
4. Ogawa K, Oishi M, Mizutani T, Maejima S, Mori T. Dural arteriovenous fistula on the convexity presenting with pure acute subdural hematoma. *Acta Neurol Belg* 2010; 110(2): 190–2.
5. Tanei T, Fukui K, Wakabayashi K, Mitsui Y, Inoue N, Watanabe M. Dural arteriovenous fistula in the anterior cranial fossa - Four case reports. *Neurol Med Chir* 2008; 48(12): 560–3.
6. Maiuri F, Iaconetta G, Sardo L, Briganti F. Dural arteriovenous malformation associated with recurrent subdural haematoma and intracranial hypertension. *Br J Neurosurg* 2001; 15(3): 273–6.
7. Kobayama S, Ishihara S, Yamane F, Kanazawa R, Ishihara H. Dural arteriovenous fistula presenting as an acute subdural hemorrhage that subsequently progressed to a chronic subdural hemorrhage: Case report. *Minim Invasive Neurosurg* 2009; 52(1): 36–8.

Received on May 22, 2016.  
Revised on August 19, 2019.  
Accepted October 10, 2019.  
Online First October, 2019.